

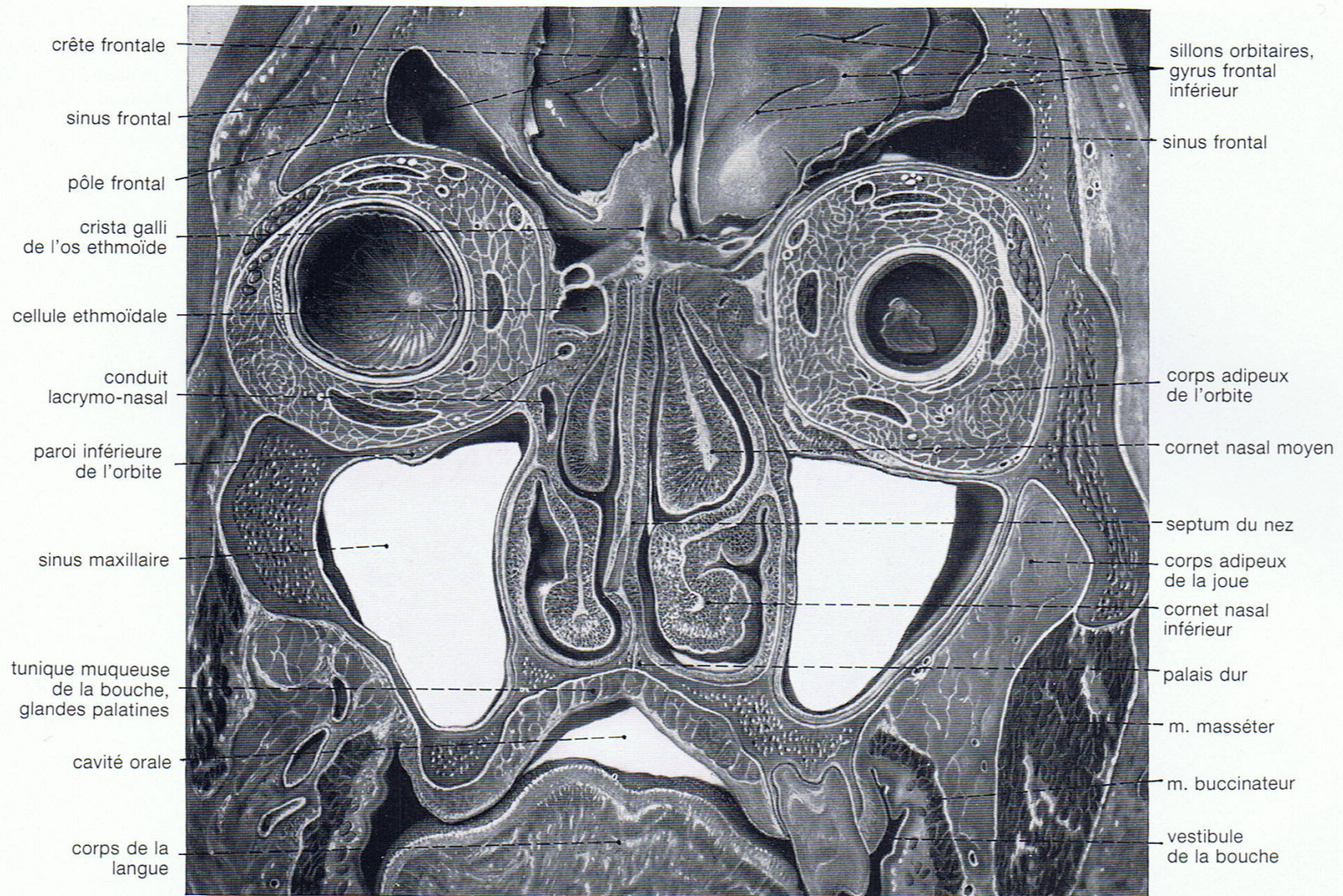

La chirurgie endoscopique des fosses nasales et des sinus

J Daele

ORL-Chirurgie cervico faciale

CHR Citadelle Liège

ANATOMIE





Scanner sinus

Image normal

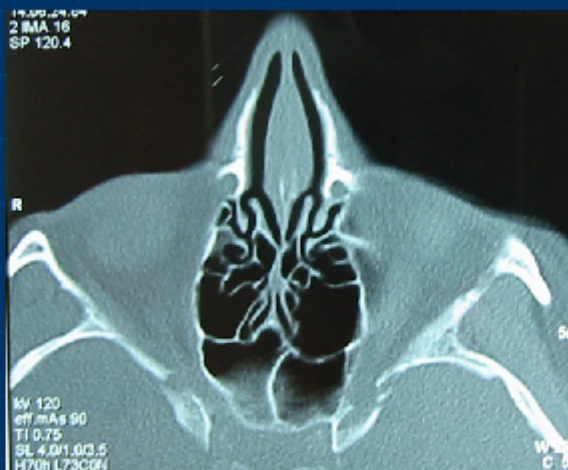
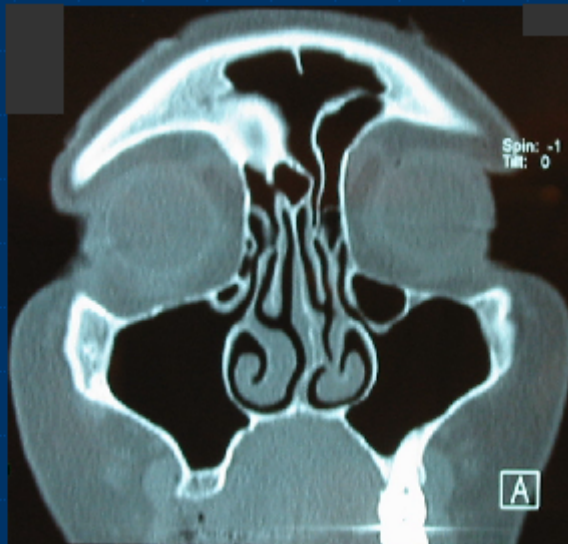
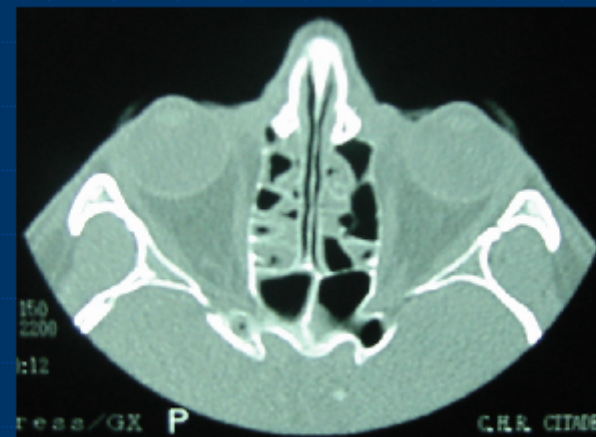
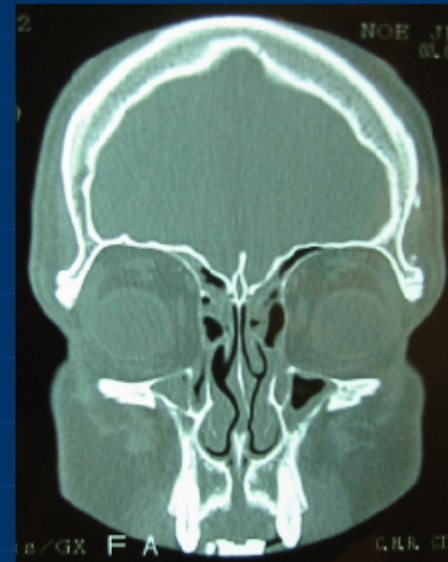
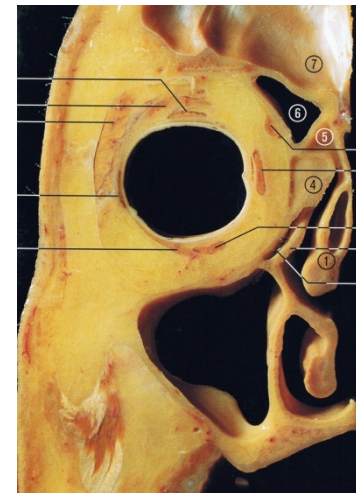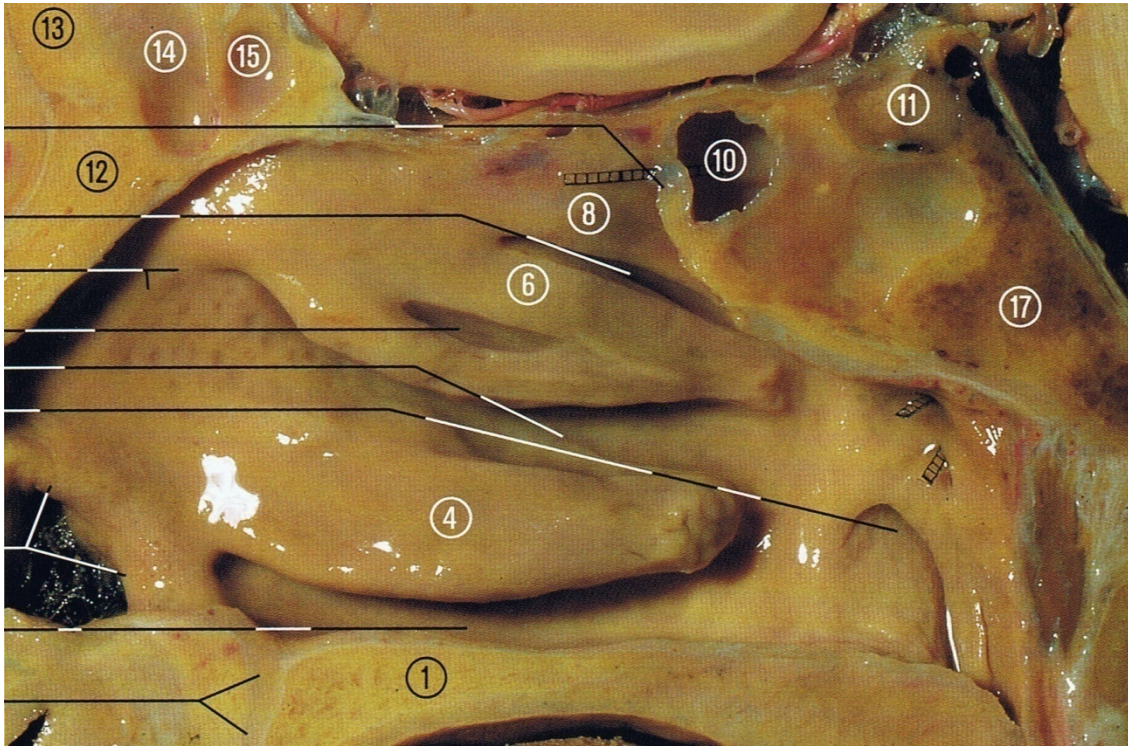


Image hyperplasique





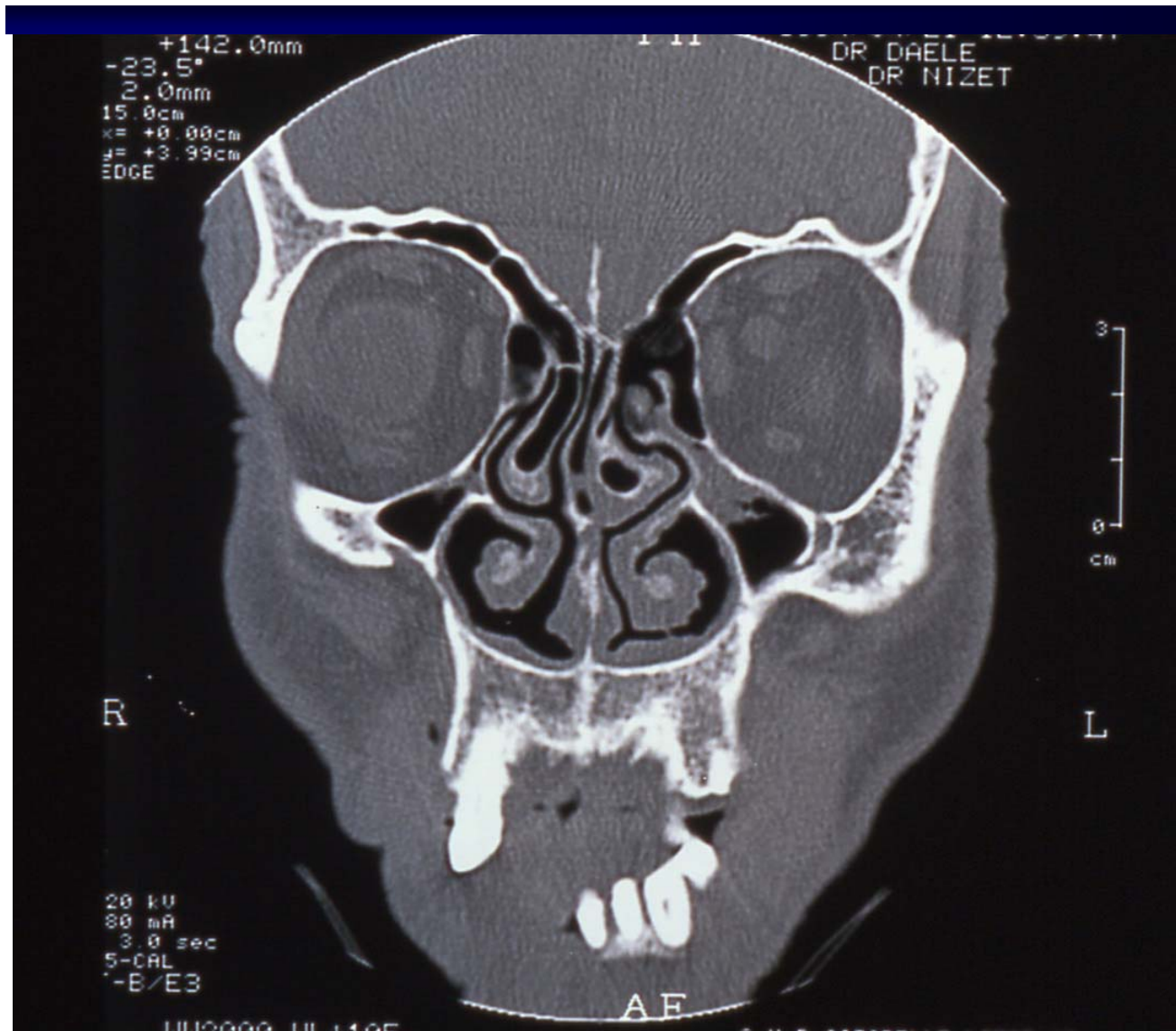
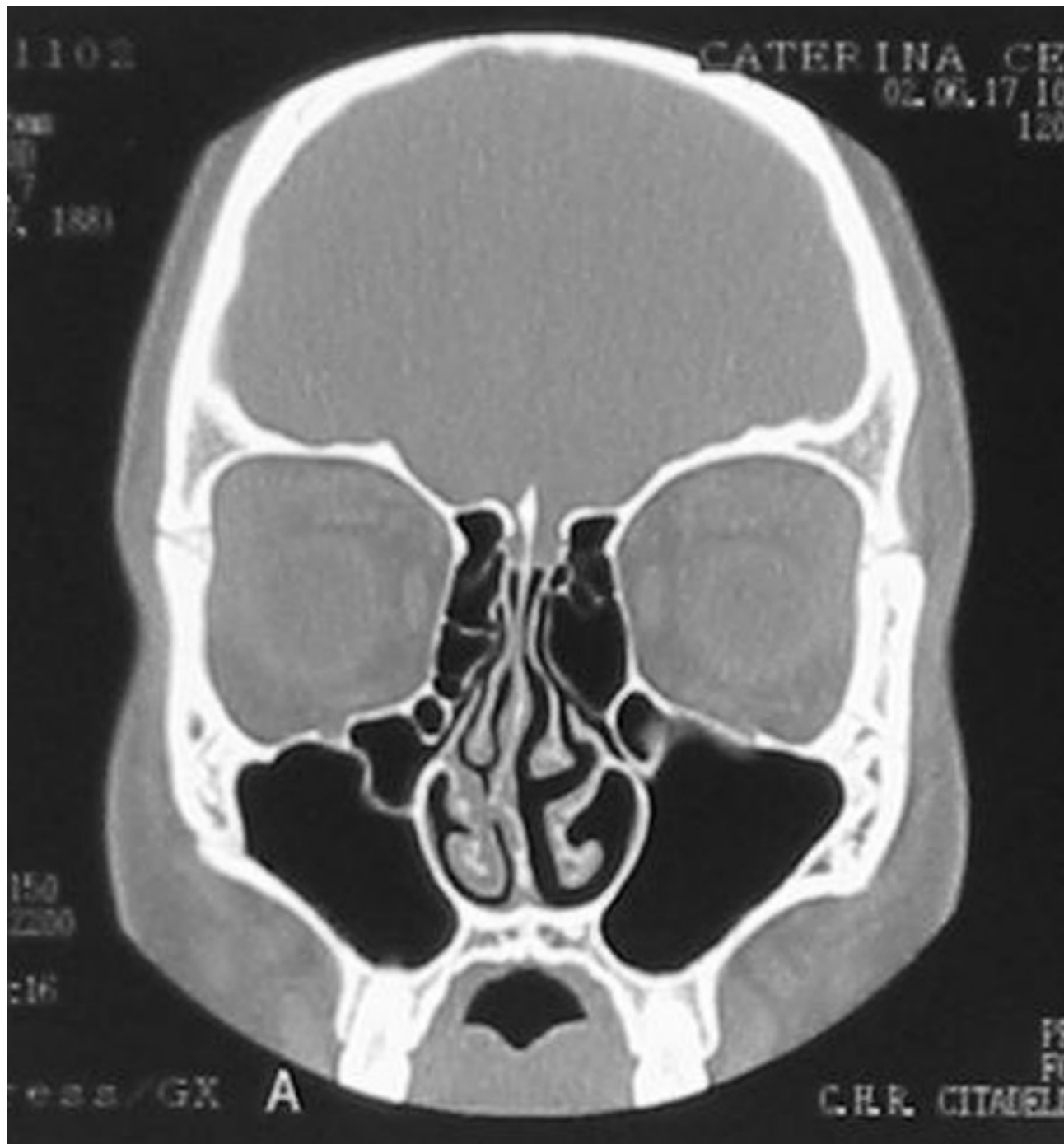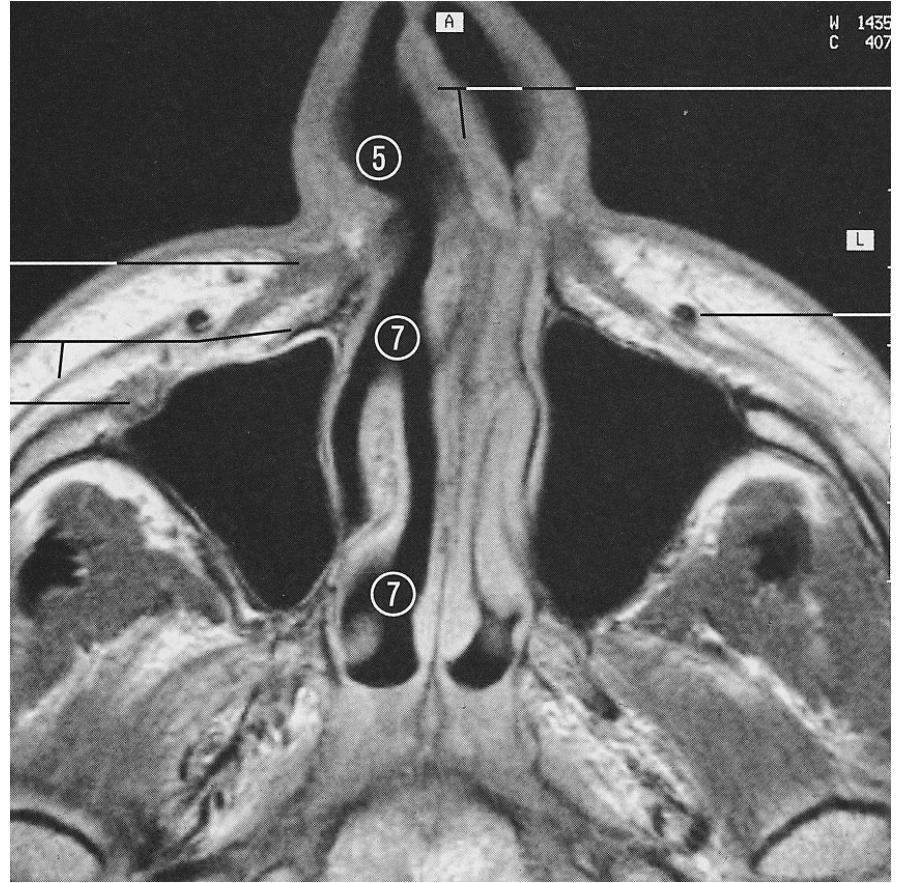
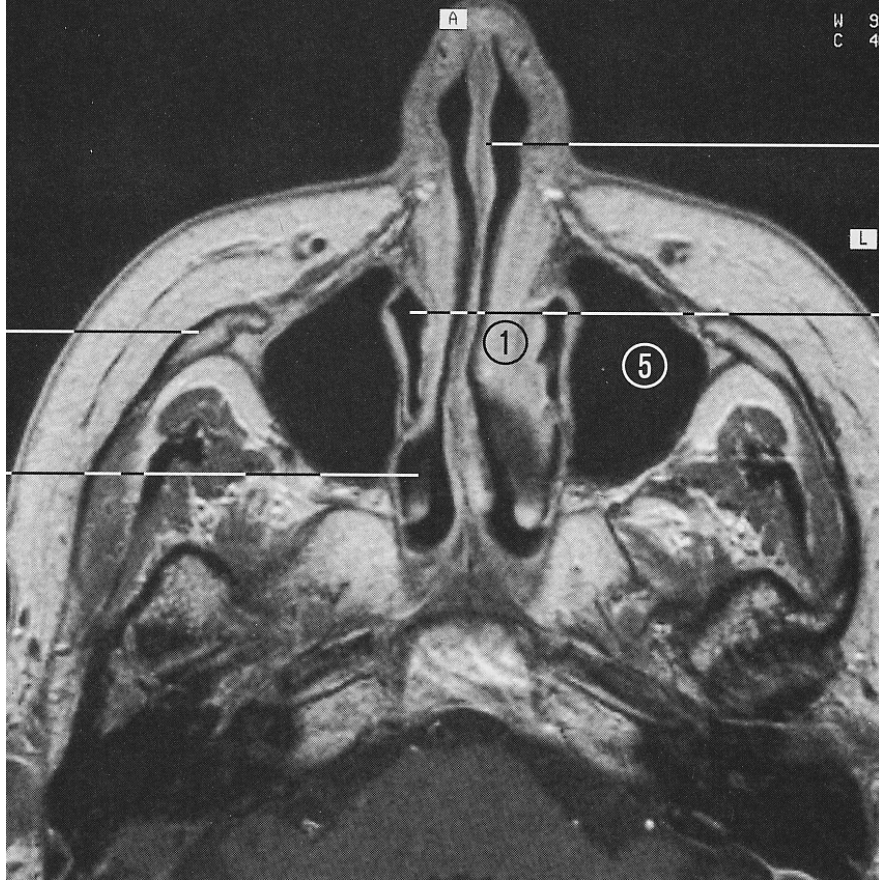
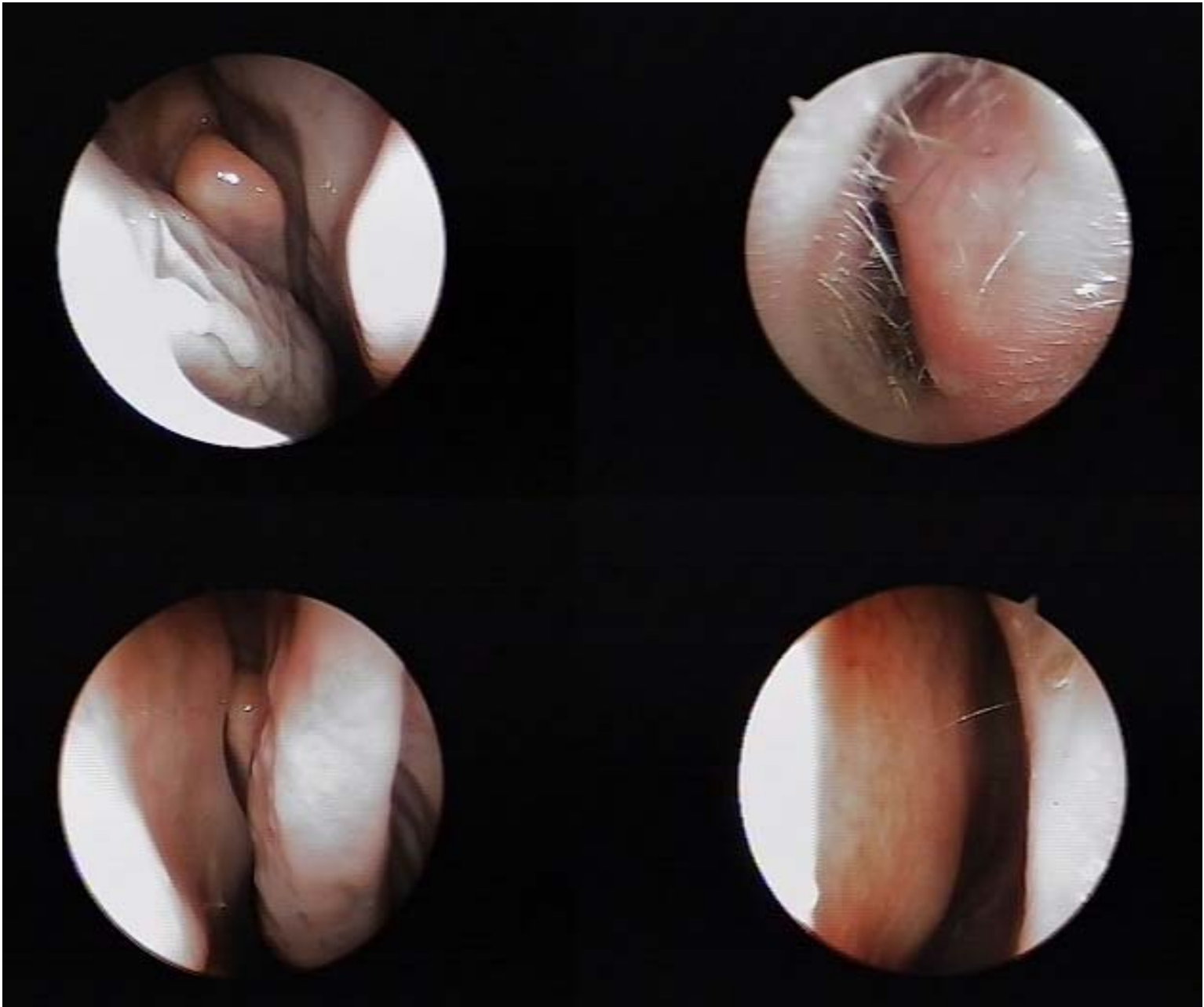

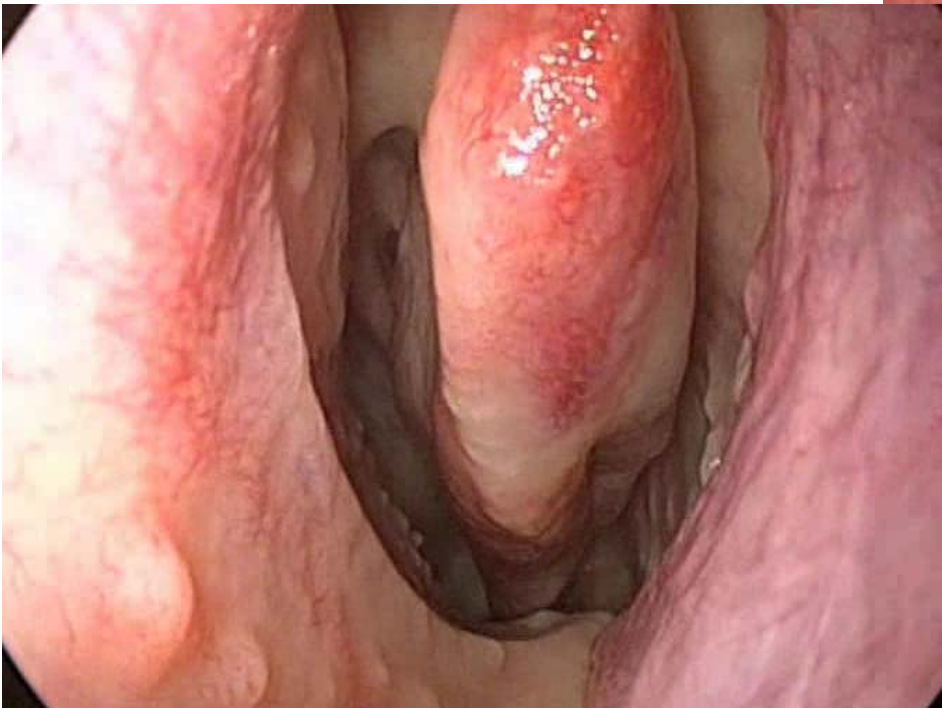
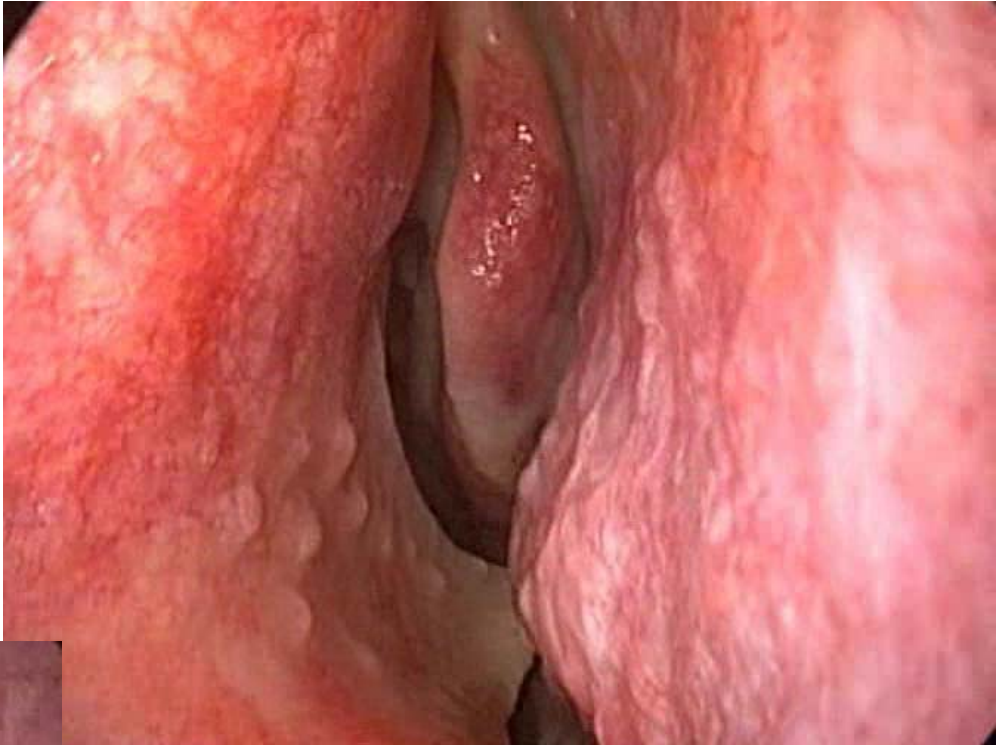Fig. 11

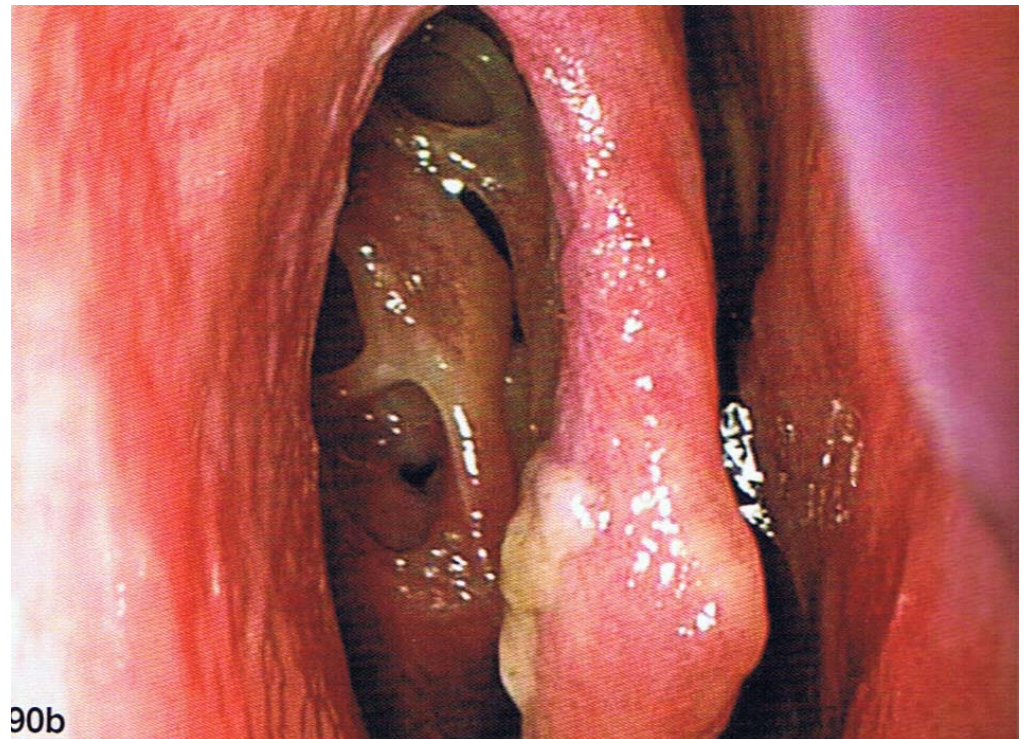


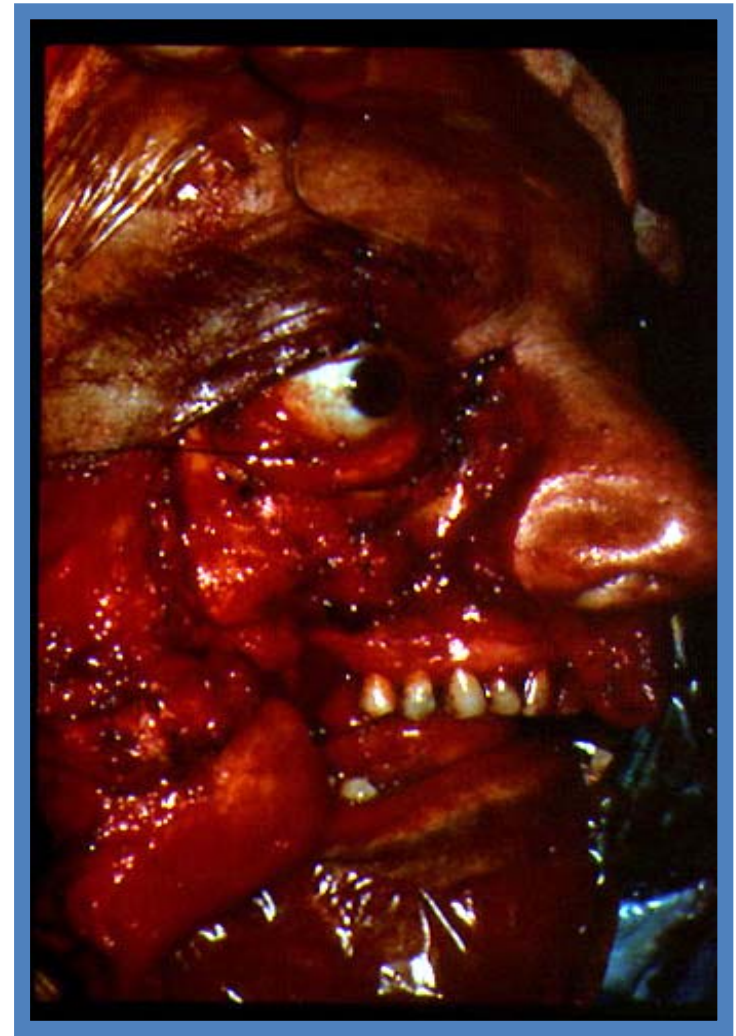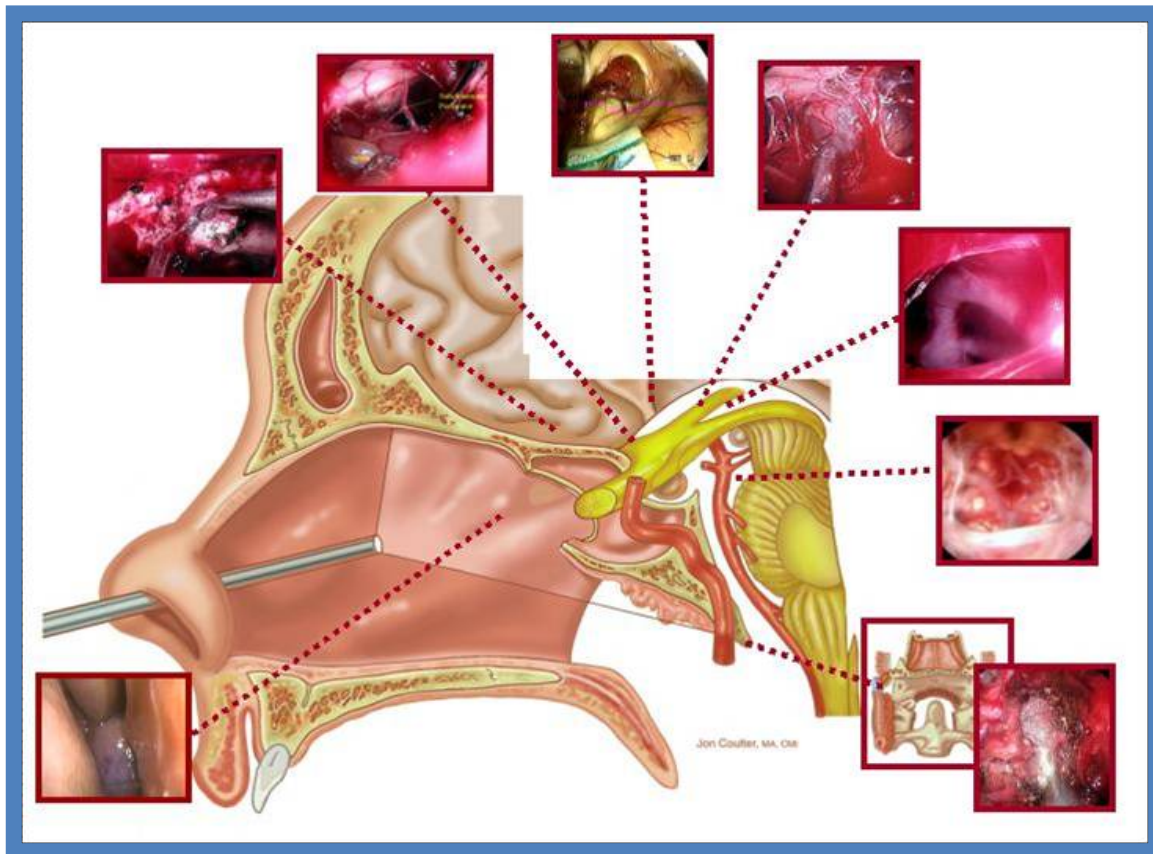


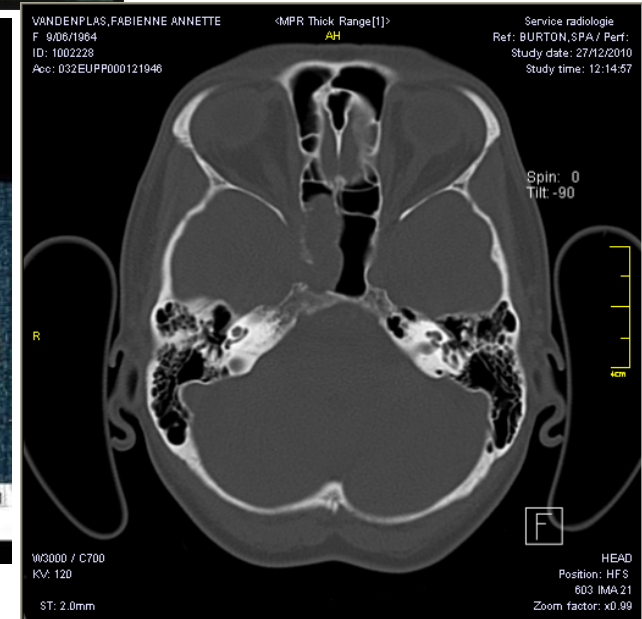
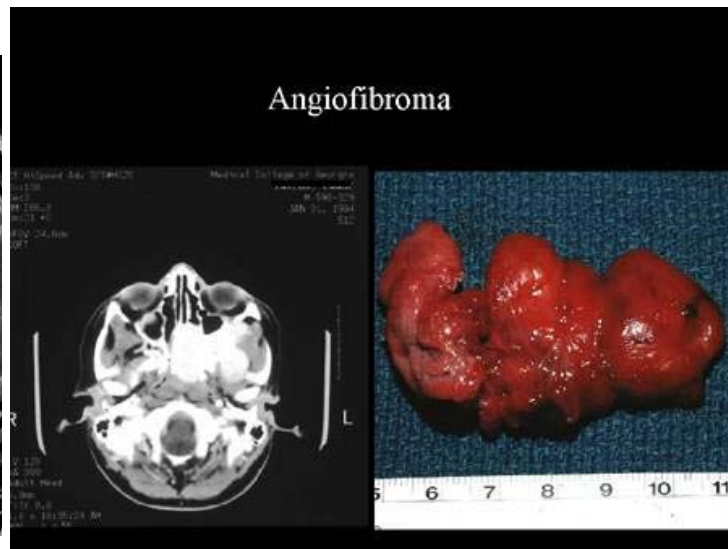
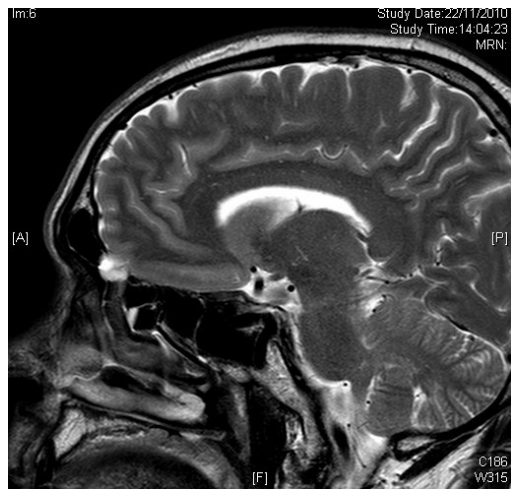
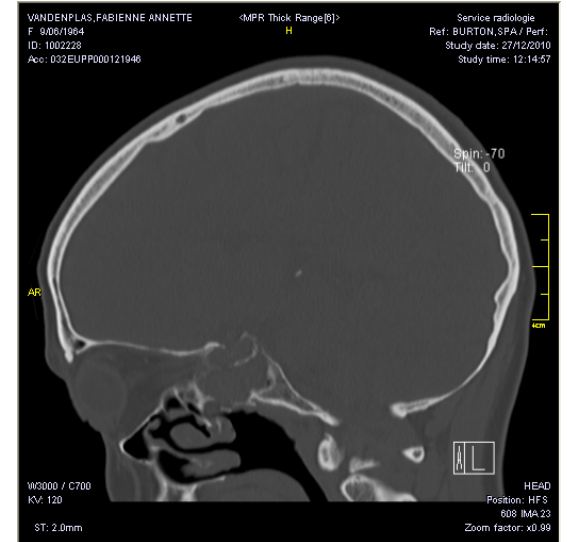
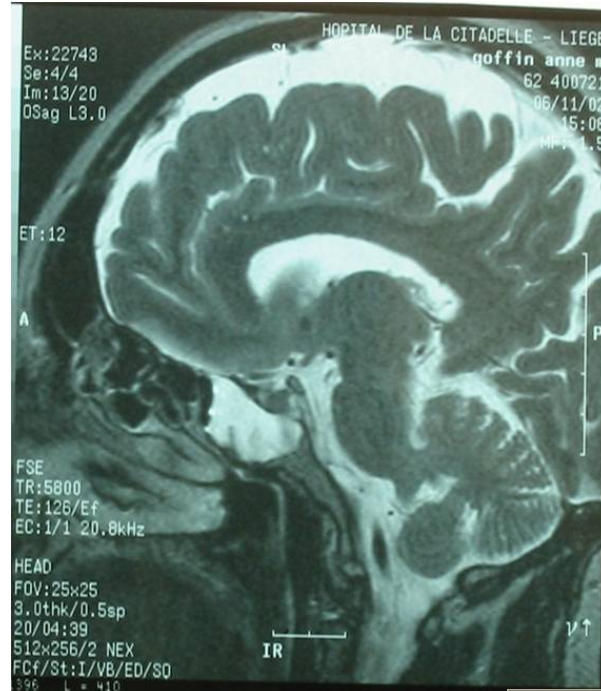
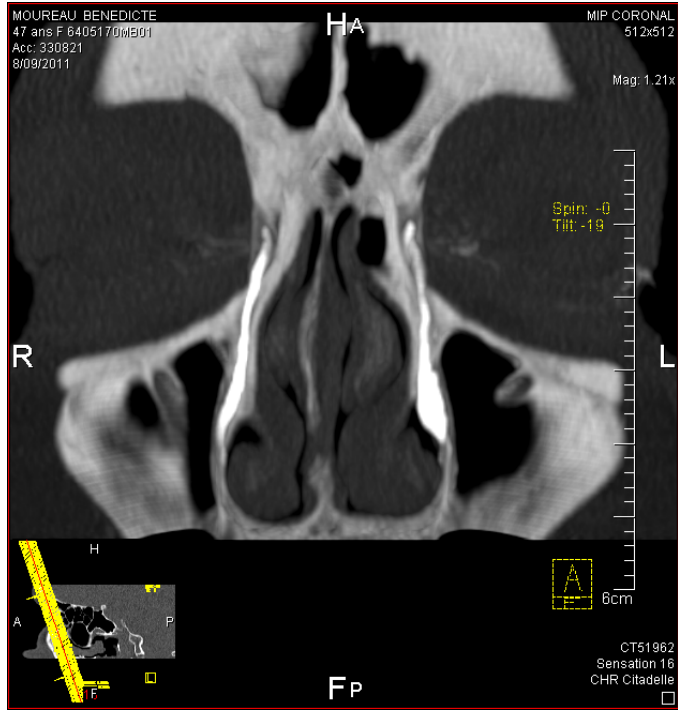


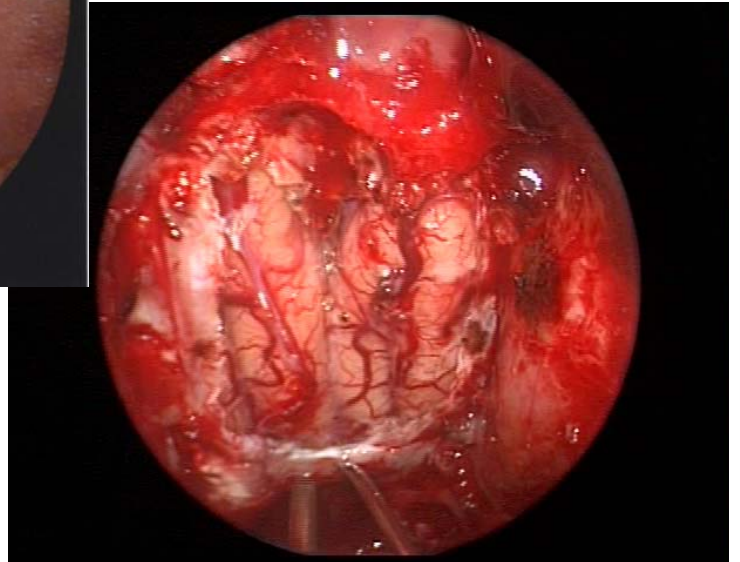
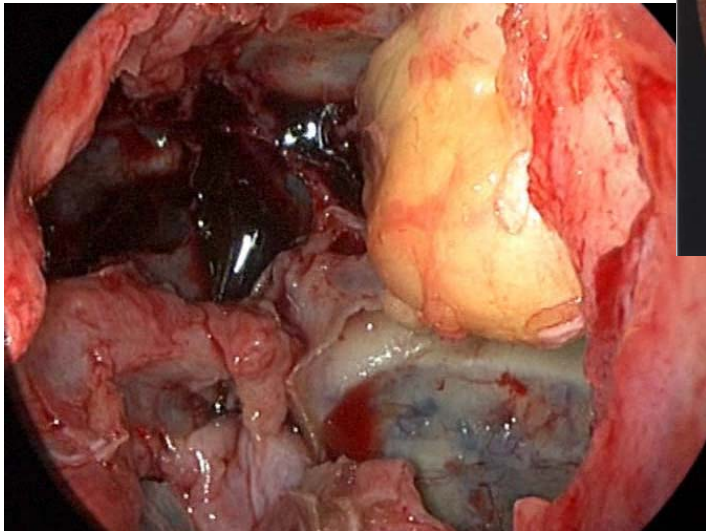
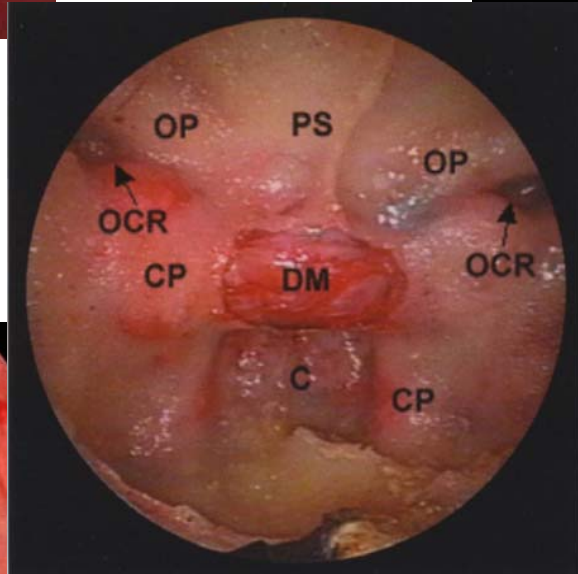
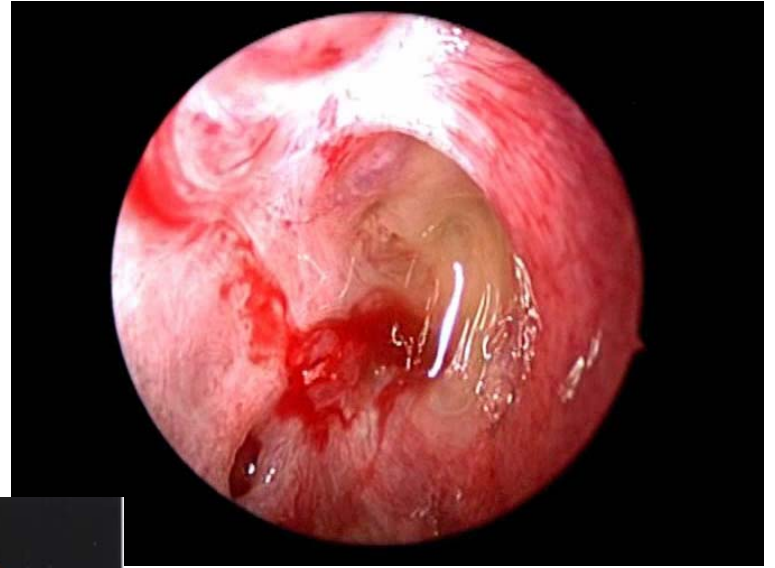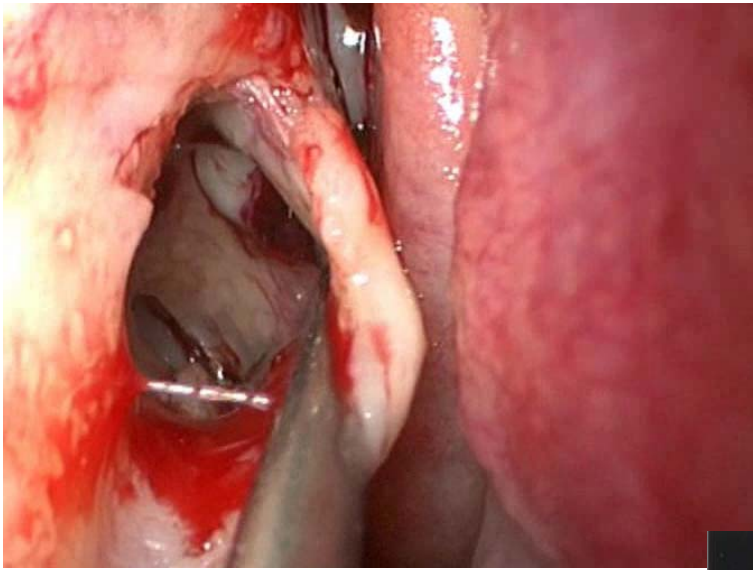


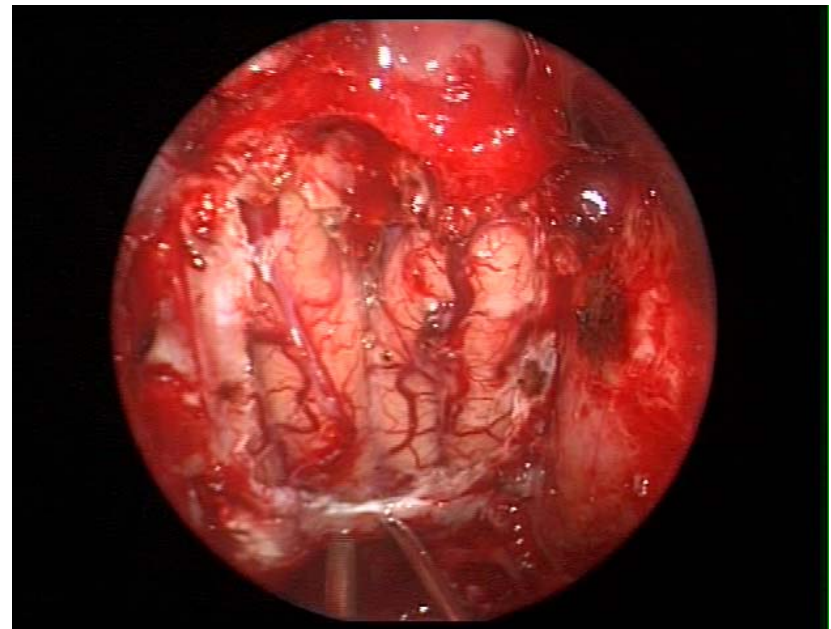
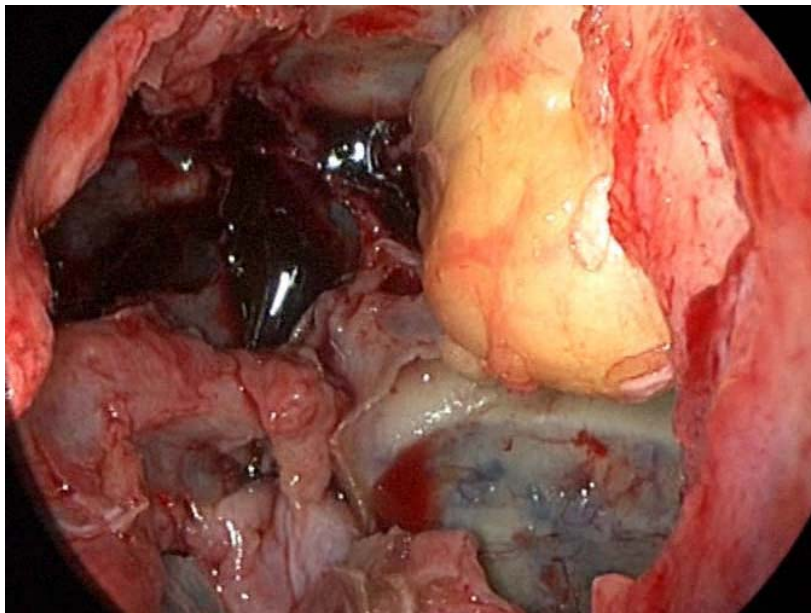
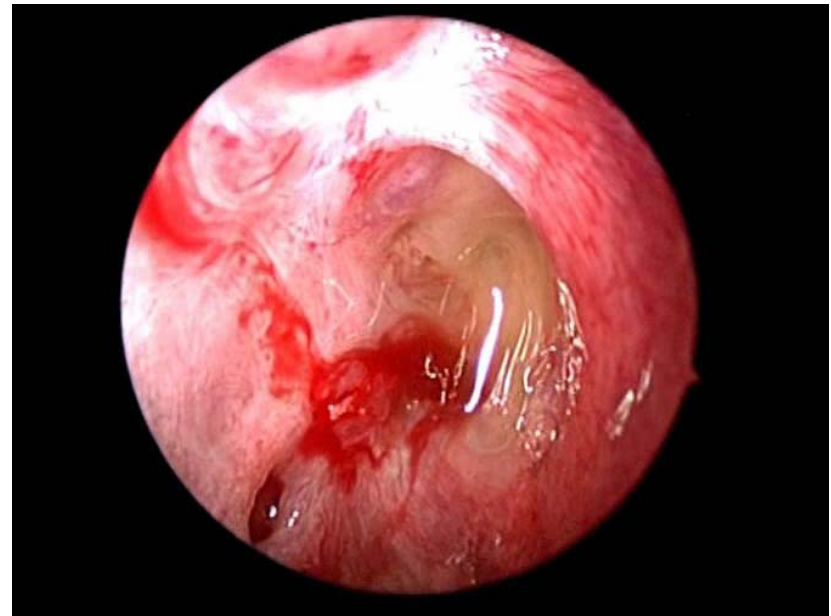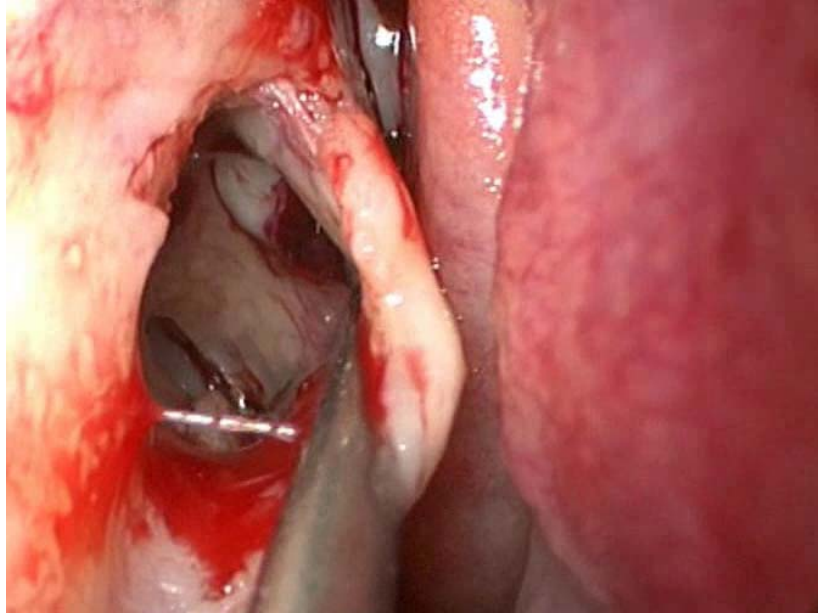
LES ABORDS



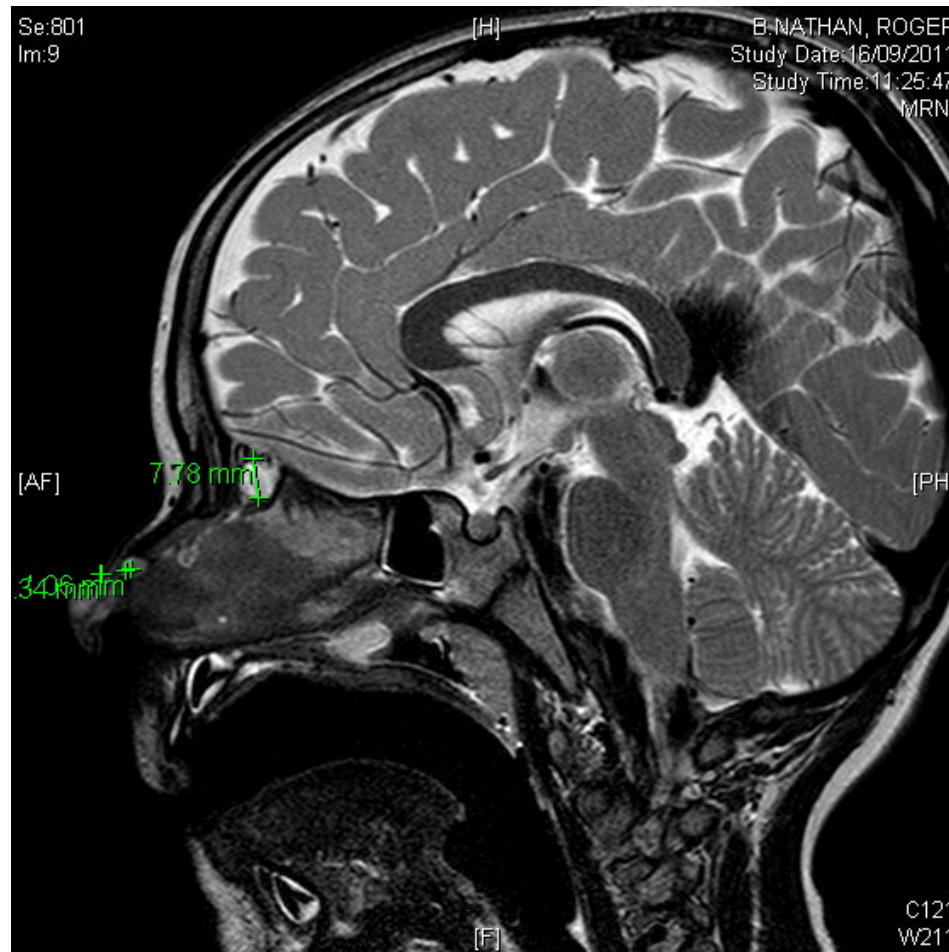


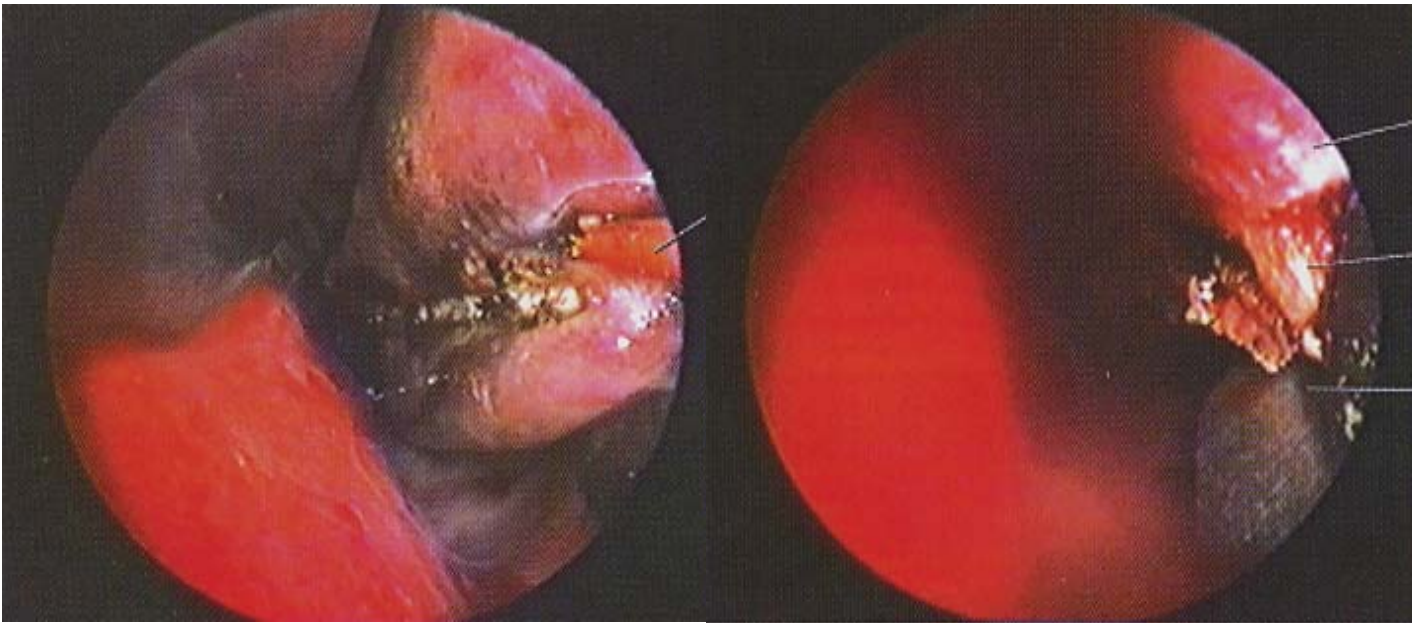
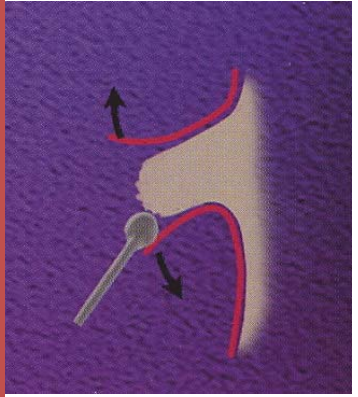
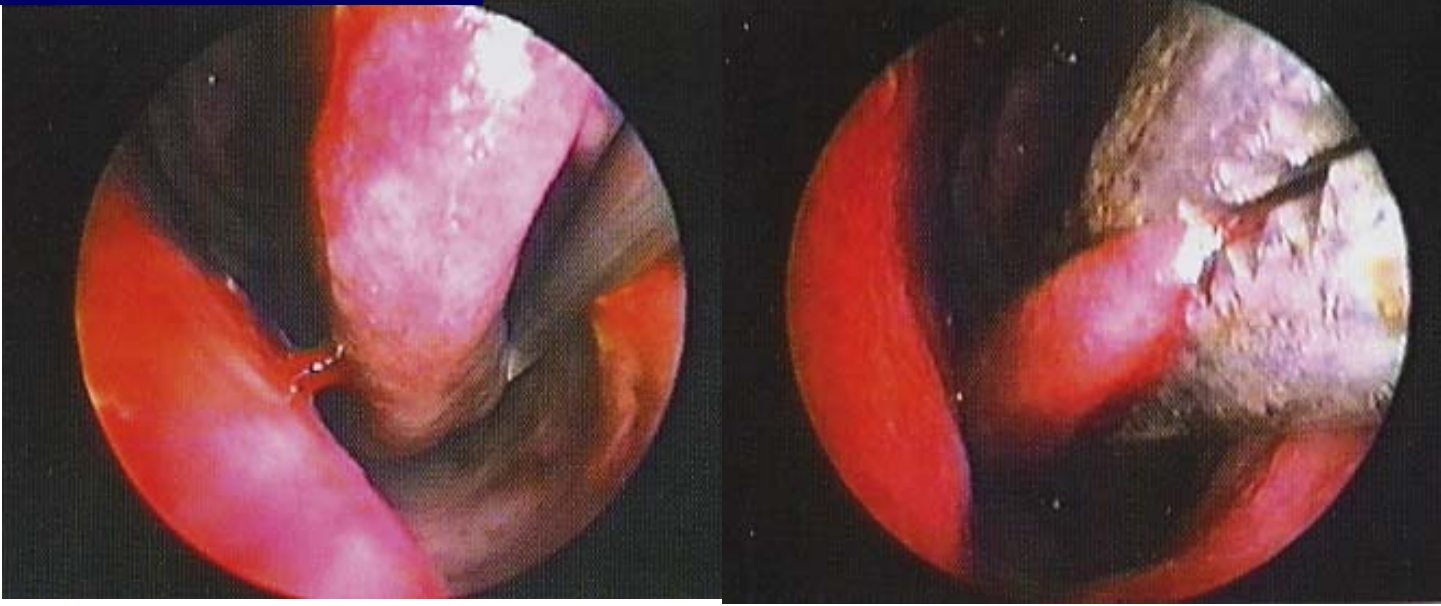


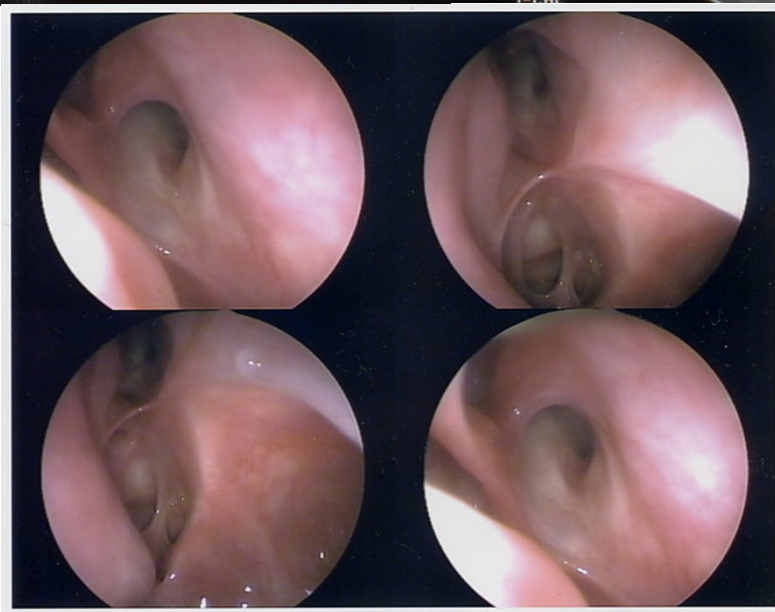
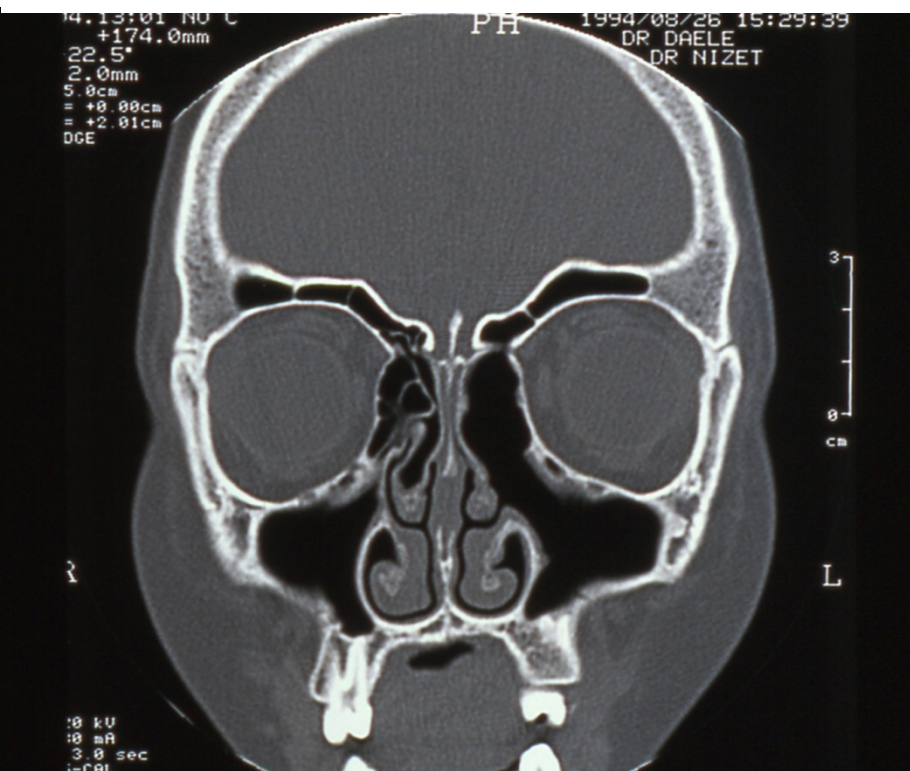
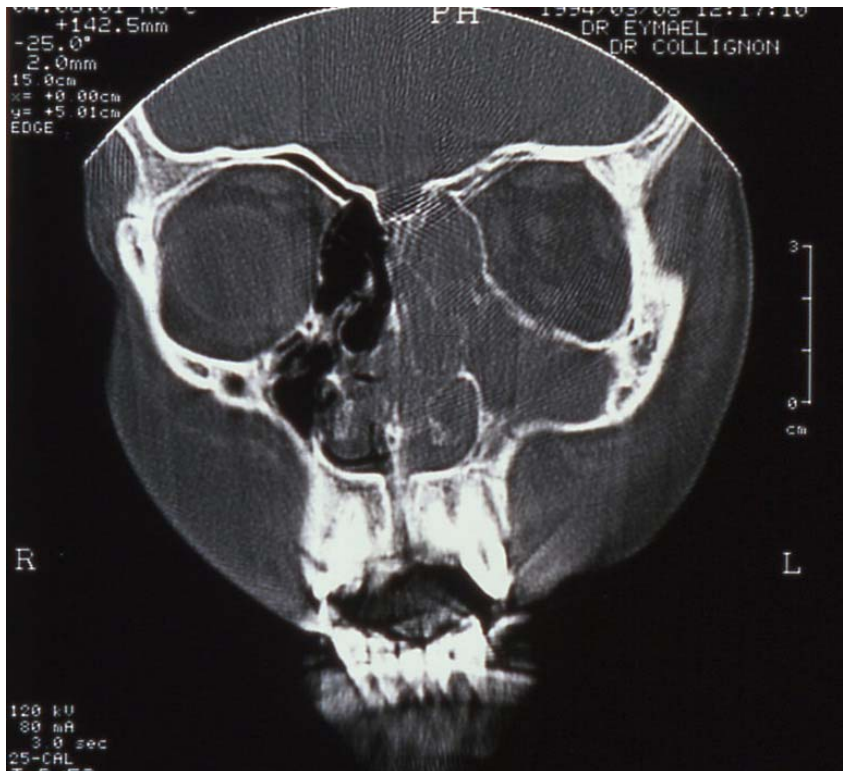




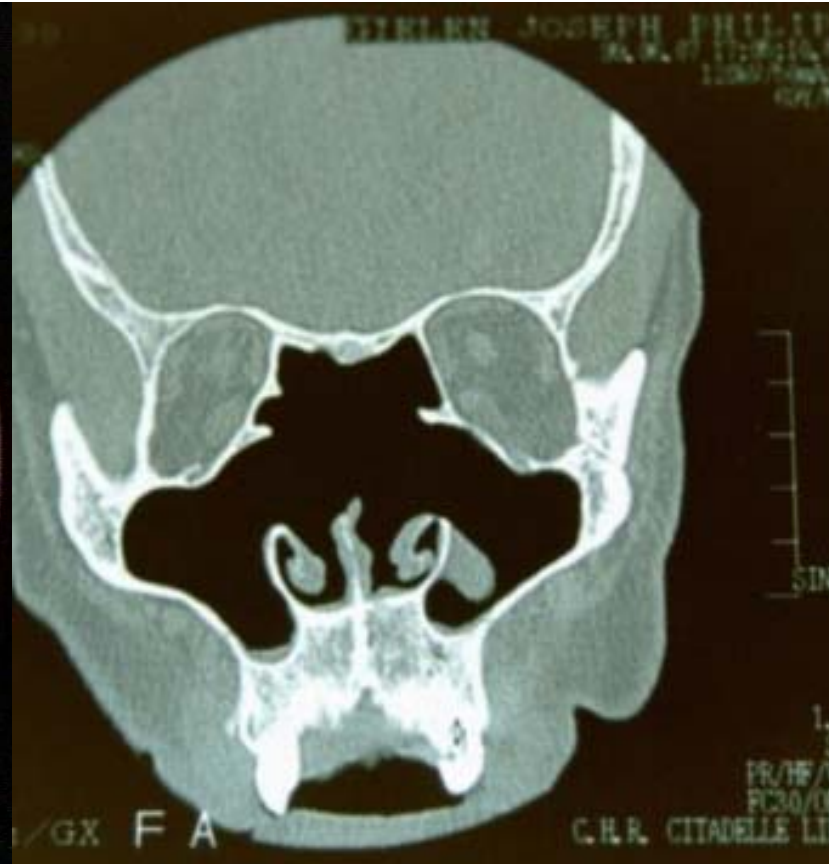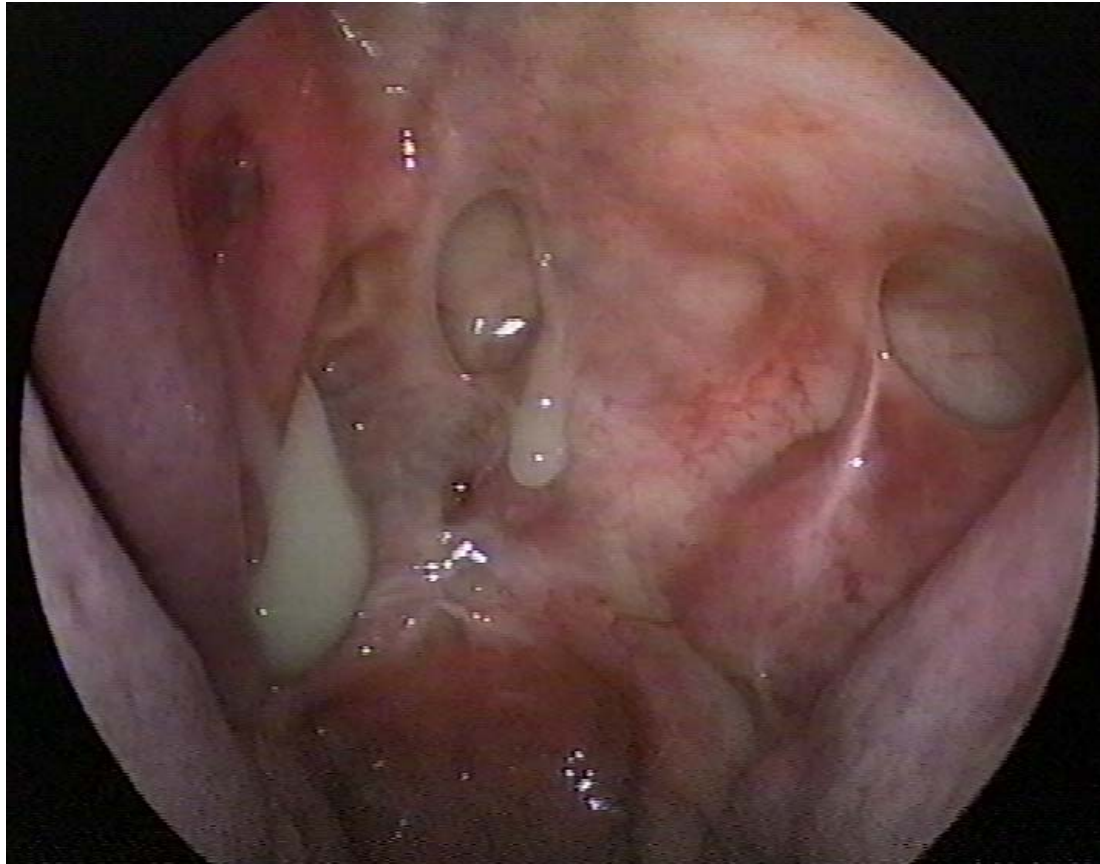
Les procédures



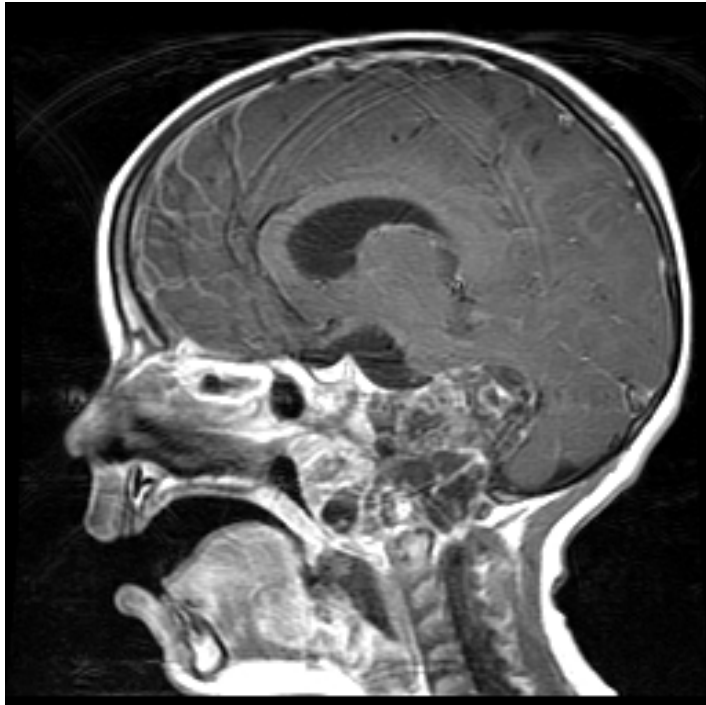




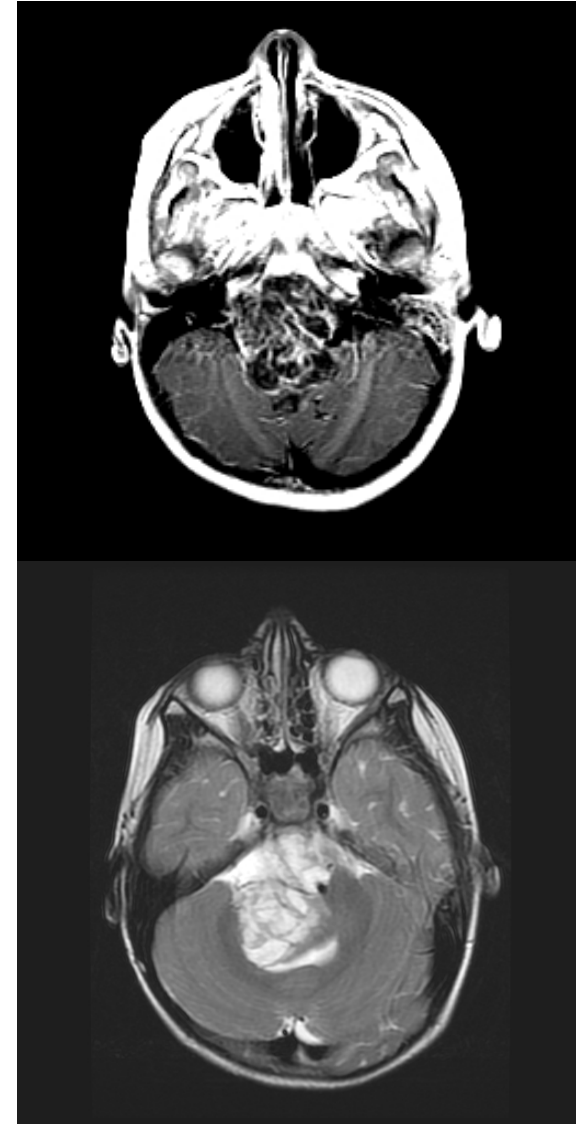Cranial base / sphenoid surgery



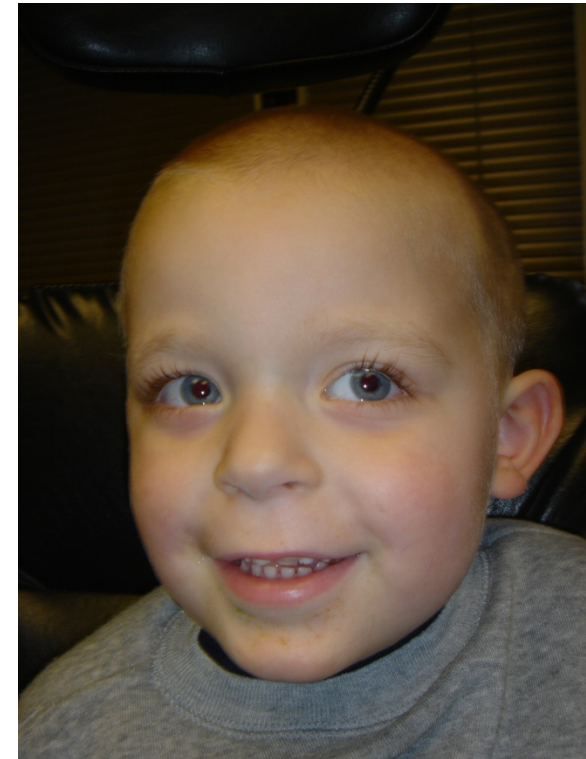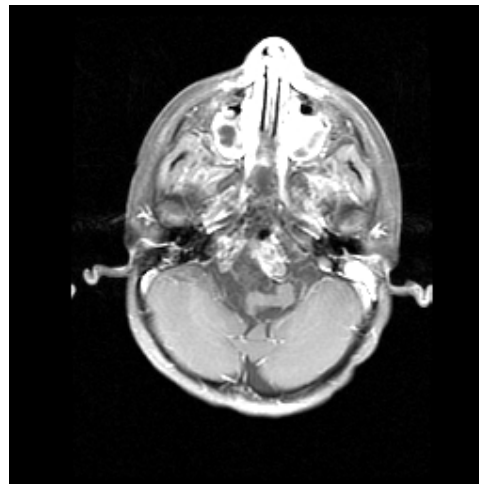
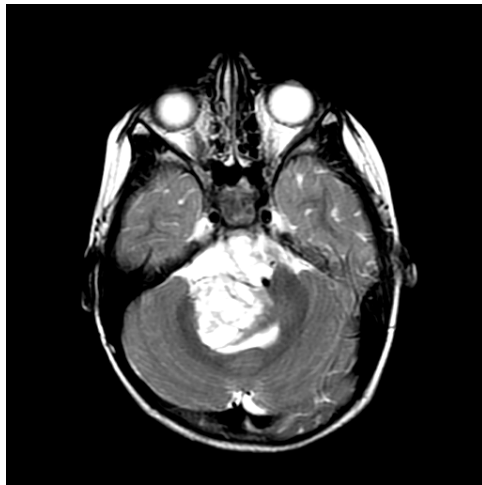
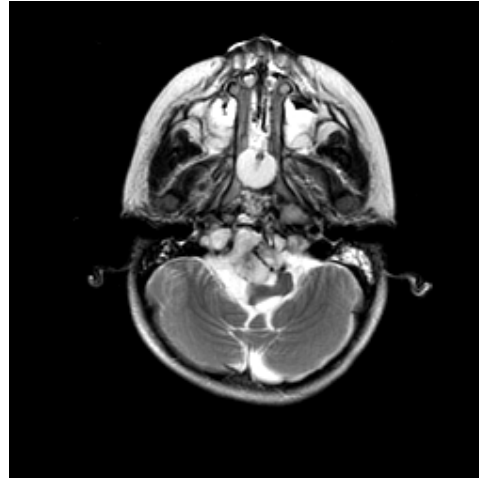
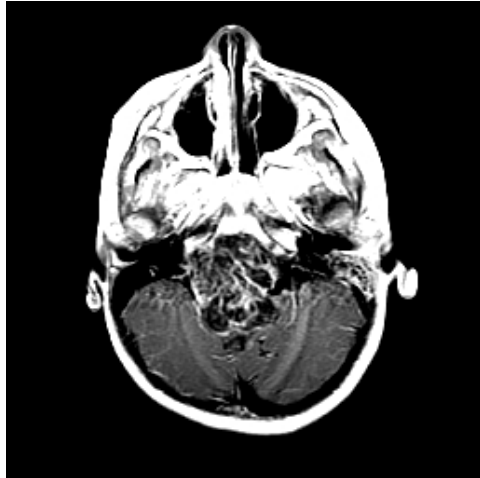
How would you remove this tumor?



- 3 year old- chordoma



Postoperative Results



PreOp

PostOp

M.I.E.M.

